

Research report

Bilateral near-infrared monitoring of the cerebral concentration and oxygen-saturation of hemoglobin during right unilateral electro-convulsive therapy

Francesco Fabbri^{a,*}, Michael E. Henry^b, Perry F. Renshaw^b, Shalini Nadgir^a,
Bruce L. Ehrenberg^a, Maria Angela Franceschini^{a,c}, Sergio Fantini^a

^aDepartment of Biomedical Engineering, Bioengineering Center, Tufts University, 4 Colby Street, Medford, MA 02155, USA

^bMcLean Hospital and Department of Psychiatry, Harvard Medical School, 115 Mill Street, Belmont, MA 02478, USA

^cNMR Center, Massachusetts General Hospital, 13th Street, Building 149, Charlestown, MA 02129, USA

Accepted 21 August 2003

Abstract

Reductions in right prefrontal cerebral blood flow have been correlated with symptomatic improvement in depressed individuals receiving electroconvulsive therapy (ECT). Non-invasive near infrared spectroscopy has previously been shown to reliably measure changes in cerebral hemoglobin concentrations and oxygen saturation. In this study, we measured the concentration and oxygen saturation of hemoglobin on the right and left frontal brain regions of nine patients during right unilateral ECT. In all patients, we have found that the electrically induced seizure causes a stronger cerebral deoxygenation on the side ipsilateral to the electrical current ($-21 \pm 5\%$) with respect to the contralateral side ($-6 \pm 4\%$). On the brain side ipsilateral to the ECT electrical discharge, we have consistently observed a discharge-induced decrease in the total hemoglobin concentration, i.e. in the cerebral blood volume, by $-7 \pm 3 \mu\text{M}$, as opposed to an average increase by $6 \pm 3 \mu\text{M}$ on the contralateral side. The ipsilateral decrease in blood volume is assigned to a vascular constriction associated with the electrical discharge, as indicated by the observed decrease in cerebral oxy-hemoglobin concentration and minimal change in deoxy-hemoglobin concentration during the electrical discharge on the side of the discharge. These findings provide indications about the cerebral hemodynamic/metabolic mechanisms associated with ECT, and may lead to useful parameters to predict the individual clinical outcome of ECT.

© 2003 Elsevier B.V. All rights reserved.

Theme: Disorders of the nervous system

Topic: Neuropsychiatric disorders

Keywords: Electro-convulsive therapy; Near-infrared spectroscopy; Seizure; Cerebral hemodynamics

1. Introduction

Electroconvulsive therapy (ECT) is a powerful somatic antidepressant treatment currently used in Psychiatry [30]. While its mechanism of action is still unclear, brain imaging studies have shown that decreases in blood flow [20] and glucose utilization [12] in the right prefrontal cortex correlate with symptomatic improvement. During a single ECT treatment, a grand mal seizure is induced while the patient is under general anesthesia. The electrode placements can vary between unilateral over the non-dominant cerebral hemisphere,

and bifrontotemporal (bilateral) placement [5]. Nobler et al. [20] have previously demonstrated that the effects of unilateral electrode placement on regional blood flow are mostly restricted to the ipsilateral cerebral hemisphere, whereas the effects of bilateral placement are evident in both hemispheres. Unilateral ECT has been associated with fewer cognitive side effects than bilateral ECT. However, the clinical efficacy of unilateral ECT appears to be less than that of bilateral ECT [22]. Therefore, identifying patterns of cerebral blood flow and oxygenation would not only be relevant to understand the physiological response to ECT, but it may also help predict eventual treatment outcome, which would be an extremely useful clinical tool.

Near-infrared spectroscopy (NIRS) is a promising technique for non-invasive functional studies of the human brain.

* Corresponding author. Tel.: +1-617-627-4359; fax: +1-617-627-3151.

E-mail address: francesco.fabbri@tufts.edu (F. Fabbri).

It has been shown that near-infrared light propagates through the intact scalp and skull [9,10,14,18] and is sensitive to regional changes in the cerebral blood flow and metabolic rate of oxygen [11,15,17,19,31]. Because seizures are associated with significant changes in the cerebral hemodynamics and oxygenation, NIRS measurements on the brain have been performed to monitor the effects of spontaneous [1,26,28,29,32] or chemically induced [34] seizures in patients with epilepsy, and chemically induced seizures in rats [13,35]. Villringer et al. [32] reported a significant increase in the cerebral blood volume (CBV) [as measured by the total hemoglobin concentration (THC)] and in the oxy-hemoglobin concentration ([HbO₂]) measured with NIRS over the presumed primary epileptogenic region during complex-partial seizures. Steinhoff et al. [29] performed NIRS measurements on the frontal region and found that the cerebral oxygen saturation consistently decreases on the side ipsilateral to the primary epileptogenic zone, while it shows minimal variations on the contralateral side. Adelson et al., who also placed the NIRS optodes on the frontal region, reported a preictal increase in cerebral oxygenation preceding the onset of seizure activity by 1–10 h, a decrease in cerebral oxygenation during seizure activity, an increase in THC and [HbO₂] during electroclinical seizures, and a decrease in THC and [HbO₂] during electrographic seizures [1]. Shichiri et al. [26] reported an increase in CBV associated with epileptic seizures, and in one case such an increase began 10 min before the seizure onset. Sokol et al. [28] measured the changes in cerebral oxygen saturation induced by complex partial seizures (CPS) and rapidly generalized CPS (RCPS) in eight patients with epilepsy using a NIRS probe placed on the patient's forehead, and found that cerebral saturation increased in the post-ictal phase for CPS (average change: $16.6 \pm 13.9\%$) but decreased for RCPS (average change: $-51.1 \pm 18.1\%$). Watanabe et al. [34] performed a bilateral multi-channel optical study on the temporal, parietal, or postcentral regions, and observed a rapid seizure-induced increase of regional CBV on the side ipsilateral to the seizure focus. In animal models, Yanagida et al. have reported an increase in the oxy-hemoglobin concentration in the rat brain during glutamate-agonist-induced epileptic seizures [35], and Hoshi et al. reported increases in THC and [HbO₂] in the rat brain during seizures induced by Pentylentetrazol injection [13]. All these studies consistently found an increase in CBV (or cerebral THC) during spontaneous or chemically induced seizures. By contrast, during electrically induced seizures in bilateral ECT, a NIRS study performed with a single optical probe placed on the patient's forehead has found a biphasic change of the cerebral THC and [HbO₂], with an initial decrease followed by an increase beyond the baseline value [23]. The concentration of deoxy-hemoglobin ([Hb]) showed an opposite biphasic behavior, with an initial increase and a subsequent decrease [23]. A later study by the same group found that the cerebral oxygenation behaves similarly to the cerebral THC and [HbO₂] during ECT, with an initial deoxygenation followed by an increase in the cerebral oxy-

genation beyond the baseline value [24]. On the basis of these results, Saito et al. concluded that the increased cerebral metabolic rate of oxygen induced by ECT may not be initially compensated by an adequate increase in cerebral blood flow, and that rapid changes in the mean arterial pressure may temporarily overwhelm cerebral pressure autoregulation [24].

In this article, we report a NIRS study performed on nine patients during right unilateral ECT. We performed bilateral NIRS recordings of the concentrations of oxy-hemoglobin ([HbO₂]), deoxy-hemoglobin ([Hb]), total hemoglobin (THC), and the cerebral oxygenation (StO₂) in the frontal brain region. Two optical probes were placed on the right and left sides, respectively, of the upper forehead of the patients during ECT treatment. During the ECT/NIRS session, we also monitored systemic parameters such as the patient's heart rate and the arterial saturation.

2. Materials and methods

2.1. ECT protocol

Patients received intravenous methohexital (0.8–1.2 mg/kg), succinylcholine (0.5–1.0 mg/kg), and glycopyrrolate (0.2 mg) for anesthesia. The barbiturate (methohexital) was given first, and when the patient became drowsy (about 30 s later) succinylcholine was injected to paralyze the patient. After one additional minute had elapsed the ECT treatment was delivered. ECT was performed using a Spectrum 5000Q device (Mecta, Lake Oswego, OR) that delivers a train of 0.14 ms/0.8 A electrical pulses with a repetition rate of 60 Hz for a total duration of 3 s (180 pulses). The electrical discharge induces a seizure that has a duration usually in the range of 30–180 s; in the measurements presented in this work, the patients had seizures with duration in the range 36–120 s. We have studied nine patients who underwent right unilateral ECT treatment. The D'Elia position [4] was used for unilateral electrode placement, and seizure threshold was titrated according to the charge-dosing paradigm of Coffey et al. [2,3]. The effect of the anesthesia and muscle relaxant guaranteed a lack of motion of the patient's head during the protocol. This prevented motion artifacts in the NIRS recordings with the only possible exception of muscle contractions during the 3 s of electrical current delivery. Frontal electroencephalography (EEG), peripheral pulse oxymetry, electrocardiography (ECG), and blood pressure were measured throughout the procedure. The blood pressure was monitored every two minutes using an automated sphygmomanometer. All patients were hyperventilated to an arterial O₂ saturation of 100%, as monitored by peripheral pulse oximetry.

2.2. NIRS instrumentation and methods

The NIRS instrument is a two-channel frequency-domain tissue spectrometer (OxiplexTS, ISS, Champaign,

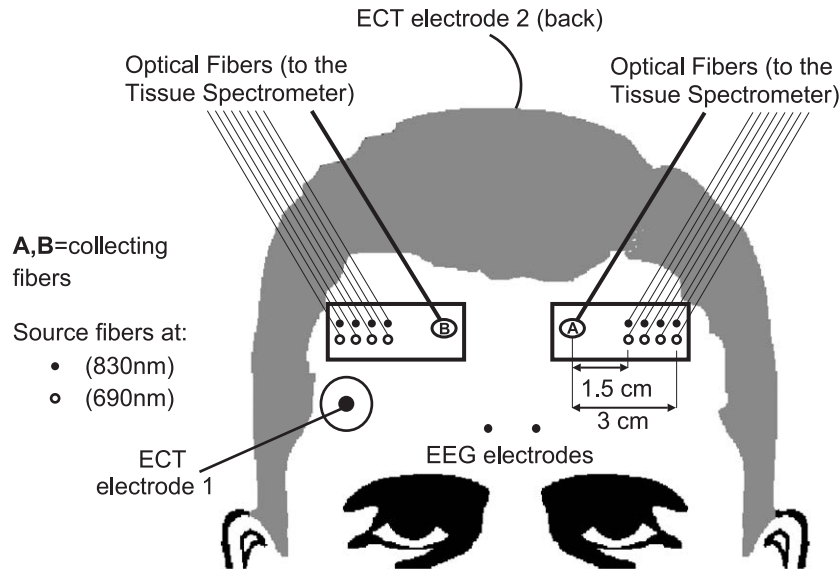


Fig. 1. Location of the optical probes on the patient's forehead, ECT electrodes, and EEG electrodes.

IL). This instrument features sixteen intensity-modulated laser diodes, eight emitting at a wavelength of 690 nm and eight at 830 nm, and two gain-modulated photomultiplier tube detectors (PMTs). The light sources are electronically multiplexed at a frequency of 100 Hz (10 ms on-time per laser diode) to time-share the two optical detectors. The modulation frequency of the laser intensity is 110 MHz, and the cross-correlation frequency for heterodyne detection is 5 kHz (in other words, the gain of the PMTs is modulated at a frequency of 110.005 MHz). The 16 laser diodes and the two PMTs are coupled to optical fibers whose other ends are arranged on two optical probes. The two optical probes are placed on the right side (ipsilateral to the ECT electrical discharge) and left side (contralateral to the ECT electrical discharge), respectively, of the

patient's forehead, as shown in Fig. 1. Each optical probe contains eight illumination optical fibers (four guiding light at 690 nm and four at 830 nm) and one collection optical fiber. Multimode glass fibers (core diameter: 400 μm) are used for illumination, while fiber bundles (internal diameter: 3 mm) are used for light collection. The optical fibers are arranged in the optical probes according to a multi-distance scheme, where the four illumination points at each wavelength are separated from the single light collection point by 1.5, 2.0, 2.5, and 3.0 cm (in patients 1 and 3, we used illumination-to-collection distances of 1.0, 1.5, 2.0 and 2.5 cm). The data from all four illumination-collection distances are analyzed using a frequency-domain multi-distance method [7] to calculate the absolute values of the oxy-hemoglobin concentration ($[\text{HbO}_2]$), deoxy-hemoglo-

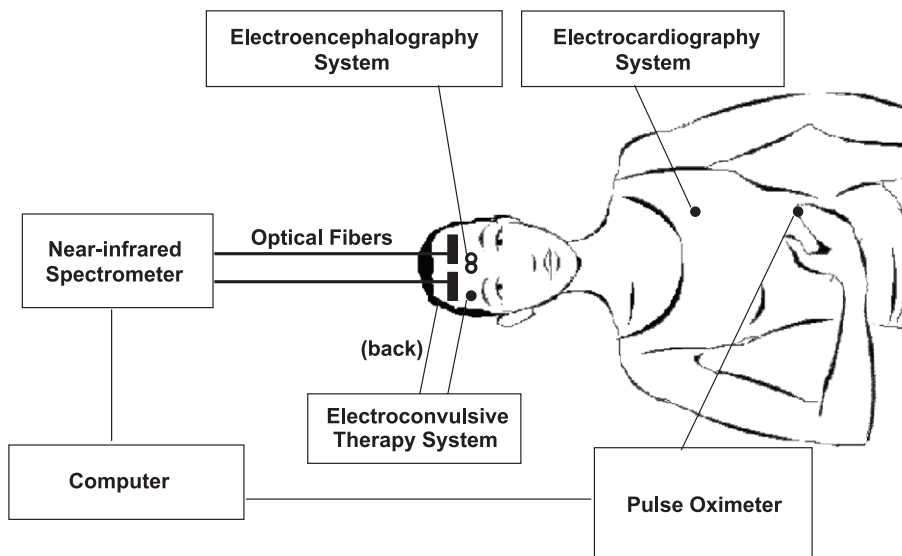


Fig. 2. Illustration of the instruments connected to the patient for electro-convulsive therapy and optical/physiological monitoring.

bin concentration ([Hb]), total hemoglobin concentration (THC), and oxygen saturation of hemoglobin (StO₂) in the tissue. This multi-distance approach to NIRS is relatively insensitive to superficial tissue layers [8]. Because of the multiplexed illumination scheme used in this NIRS instrument, it takes 80 ms to cycle through the eight laser diodes in each optical probe (two wavelengths, four illumination–collection distances). This sets an instrumental limit to the temporal resolution of our measurements. However, since these measurements are aimed at measuring cerebral hemodynamics and oxygenation changes occurring on a time scale of seconds, we have averaged 10 consecutive data points (corresponding to 0.8 s of acquisition) to improve the signal-to-noise ratio of our measurements. The NIRS data are recorded concurrently with the pulse oximeter data (heart rate and arterial saturation) by connecting the analog outputs of the pulse oximeter to the auxiliary inputs of the NIRS spectrometer. The NIRS data are synchronized with the EEG and ECG data by using the ECT electrical discharge as a well-defined reference event.

We started the acquisitions of NIRS data before the Barbiturate was injected into the patient, which occurs about 2 min before the administration of the electrical discharge for ECT. We continued the NIRS acquisitions through the electrically induced seizure and for 20–120 s after the end of the seizure as recorded by EEG. In one case (patient 1) we had to stop the NIRS recording before the end of the seizure for technical reasons; however, we did not exclude patient 1 from our study because the data recorded for 65 s after the ECT discharge were enough for the elaborations presented in this work.

To quantify the changes in THC and in StO₂ caused by the electrically induced seizure, we computed the maximal variation between the data recorded in the first 30 s after the end of the discharge and the pre-discharge value. The pre-discharge value was obtained by averaging the baseline data during the 10 s immediately preceding the discharge. The differences in the changes of THC and StO₂ between the ipsilateral and contralateral side are analyzed with a *t*-test and the criterion for significance is $P < 0.01$.

2.3. Patients

The experimental arrangement for the ECT/NIRS session is illustrated in Fig. 2, which shows the NIRS spectrometer, the pulse oximeter, and the electroconvulsive, electroencephalography, and electrocardiography systems connected to the patient. The protocol for this study was approved by the Institutional Review Board of McLean Hospital, and all patients gave their written informed consent before participating in this study. We examined nine patients (seven males and two females), within the age range of 27–57 years. All patients were free from known cardiovascular disease and they were suffering from major depression. In one case (patient 5) we performed NIRS measurements during three ECT sessions; the second ses-

sion took place 4 days after the first, and the third session took place 7 days after the second.

3. Results

We found that the heart rate increased significantly in all subjects after the ECT current delivery, from a baseline value of 104 ± 10 beats/min (all data in this subsection are averages \pm standard deviations across the nine patients) to a maximum value of 178 ± 28 beats/min [the high average baseline heart rate of 104 ± 10 beats/min was attributed to patient anxiety]. The heart rate started to increase 8 ± 1 s

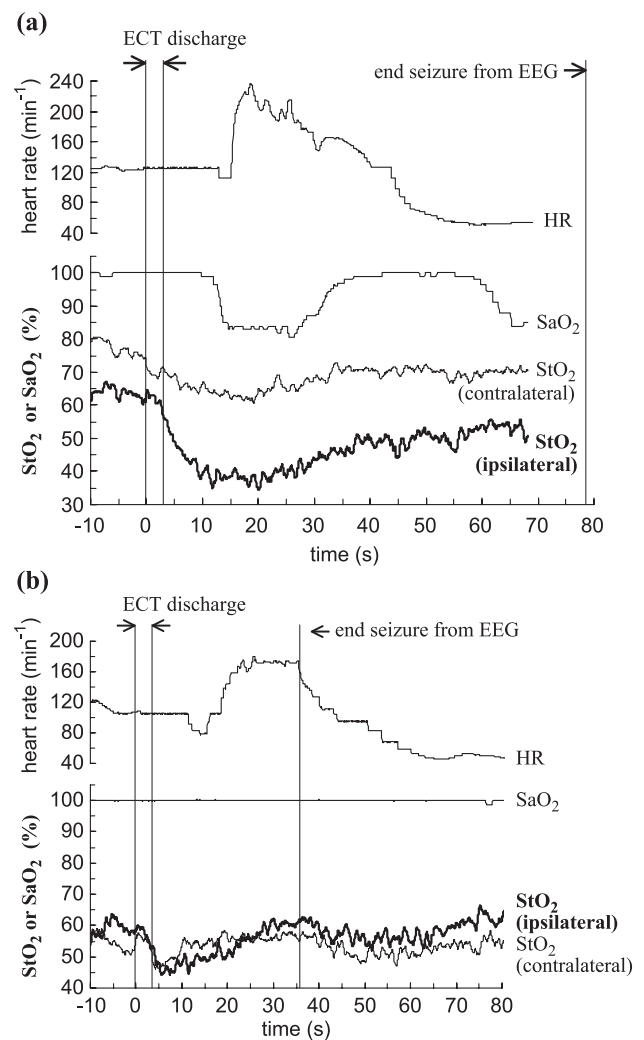


Fig. 3. Representative examples of the changes in heart rate, arterial oxygen saturation, and cerebral oxygenation observed in response to the ECT electrical discharge. (a) The case of patient 1 is characterized by a significant decrease in the arterial saturation (SaO₂) measured with pulse oximetry and by a relatively slow decrease in the cerebral oxygenation (StO₂) measured by NIRS. (b) The case of patient 7 is characterized by a lack of significant changes in SaO₂ and by a relatively fast recovery of StO₂ during the ECT discharge. In all cases, we observed a significant increase in the heart rate during seizure.

after the end of the current delivery, and reached its maximum value after 15 ± 2 s. The fact that there is a time delay between the end of the discharge and the increase in heart rate has been reported in the literature [30].

3.1. Cerebral oxygenation and arterial saturation

In all nine patients, we consistently observed a post-discharge decrease in the cerebral hemoglobin saturation on the side ipsilateral to the electrical discharge. On the contralateral side, we also typically observed a post-discharge

desaturation, with three exceptions (patients 2, 3 and 5 (3rd session)). The observed cerebral desaturation occurred according to two distinct patterns. The first pattern (illustrated in Fig. 3a which refers to patient 1) is characterized by a significant decrease in the arterial saturation during the seizure, and by a decrease in the cerebral oxygenation prompted by the ECT electrical discharge. The minimum values of cerebral and arterial oxygenation are reached 15–20 s after the ECT discharge, and are followed by a relatively slow recovery to baseline. The second oxygenation pattern (shown in Fig. 3b, which refers to patient 7) is characterized

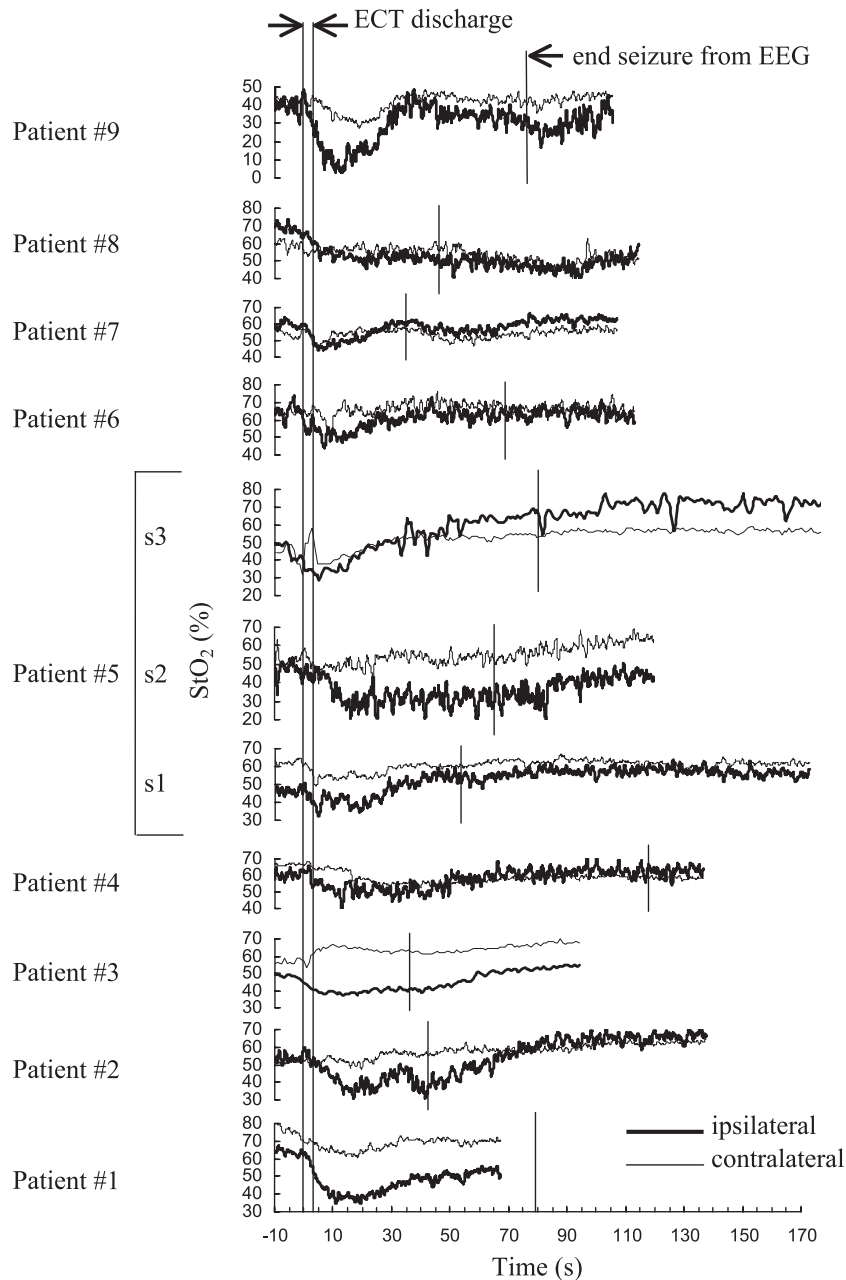


Fig. 4. Temporal traces of cerebral hemoglobin saturation (StO_2) recorded with near-infrared spectroscopy on the sides ipsilateral (right) or contralateral (left) to the application of right unilateral ECT for all patients.

Table 1

Baseline and seizure-induced changes in the cerebral total concentration of hemoglobin (THC) and in the oxygen saturation of hemoglobin (StO₂)

Patient no.	Contralateral				Ipsilateral			
	Baseline THC (μM)	ΔTHC (μM)	Baseline StO ₂ (%)	ΔStO ₂ (%)	Baseline THC (μM)	ΔTHC (μM)	Baseline StO ₂ (%)	ΔStO ₂ (%)
1	66 ± 4	11 ± 9	77 ± 2	-16 ± 4	43 ± 1	-11 ± 2	64 ± 2	-29 ± 3
2	29 ± 1	8 ± 1	52 ± 1	7 ± 2	30 ± 1	7 ± 2	54 ± 2	-23 ± 4
3	28 ± 1	9 ± 2	57 ± 2	10 ± 4	38 ± 1	-8 ± 2	49 ± 1	-12 ± 2
4	27 ± 1	-4 ± 1	67 ± 1	-14 ± 1	25 ± 1	-9 ± 2	60 ± 2	-20 ± 4
5a	41 ± 1	-8 ± 2	62 ± 1	-9 ± 2	25 ± 1	-4 ± 1	46 ± 2	-14 ± 3
5b	24 ± 1	9 ± 2	52 ± 4	-12 ± 7	29 ± 1	-7 ± 2	48 ± 4	-27 ± 8
5c	28 ± 2	5 ± 3	42 ± 1	10 ± 2	27 ± 1	-2 ± 2	45 ± 2	-15 ± 4
6	30 ± 1	-3 ± 2	64 ± 2	-13 ± 3	30 ± 4	-13 ± 9	62 ± 6	-18 ± 13
7	36 ± 2	15 ± 4	54 ± 2	-8 ± 5	35 ± 1	-7 ± 3	59 ± 2	-15 ± 4
8	40 ± 1	19 ± 3	60 ± 2	-9 ± 4	38 ± 2	-15 ± 3	69 ± 2	-23 ± 4
9	31 ± 1	4 ± 1	43 ± 2	-15 ± 3	20 ± 1	-5 ± 2	40 ± 4	-37 ± 9
Average	34 ± 1	6 ± 3	57 ± 2	-6 ± 4	31 ± 1	-7 ± 3	54 ± 3	-21 ± 5

The errors represent the standard deviation of the data.

by a lack of change in the arterial saturation, and by a discharge-induced decrease in the cerebral oxygenation that starts recovering toward the baseline value within 5 s following the ECT discharge. Patients 1, 2, 3, 4, 8 and 9 showed the first oxygenation pattern, while patients 5, 6, and 7 showed the second oxygenation pattern. Patient 5, the one that was measured during three ECT sessions, showed negligible changes in the arterial saturation in all three sessions (consistent with the second oxygenation pattern), but in the second session showed a relatively slow decrease in the cerebral oxygenation (which is a feature of the first oxygenation pattern).

The NIRS data recorded during the ~ 2 min preceding the ECT discharge showed slow (tens of seconds) fluctuations that reflected baseline hemodynamics. However, these

pre-discharge recordings were sometimes also affected by patient's motion (before anesthesia) and by the investigators' refinement of the optical probe positioning. Because these baseline NIRS recordings are not all representative of cerebral physiological processes and may confound the display of the effects of the ECT discharge, we have opted for showing and analyzing only the data recorded starting 10 s prior to the ECT discharge.

The temporal traces of the cerebral hemoglobin saturation recorded with NIRS are reported in Fig. 4 for all patients and for both recording sides. The thick lines refer to the right side (ipsilateral to the ECT discharge side) while the thin lines refer to the left side (contralateral to the ECT discharge side). Table 1 reports the baseline values of StO₂ at the ipsilateral and contralateral side

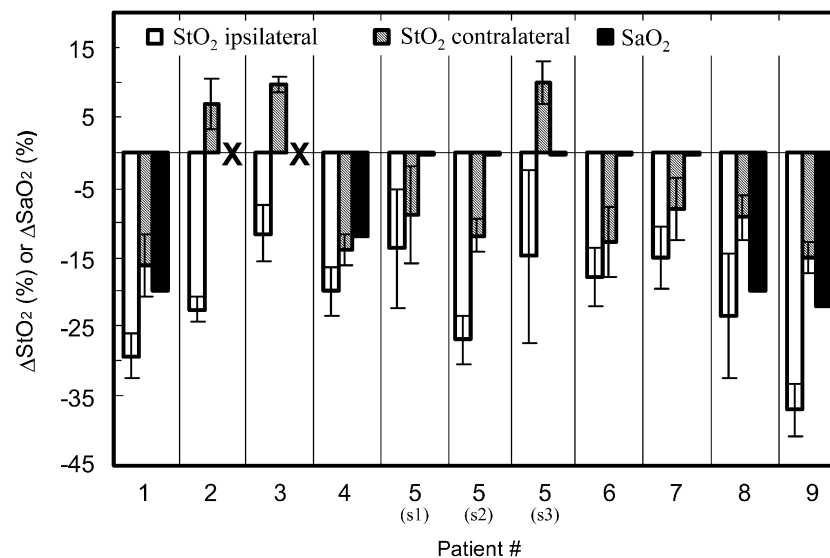


Fig. 5. Ipsilateral and contralateral changes induced by ECT in the cerebral hemoglobin saturation (StO₂) measured with NIRS and in the arterial saturation (SaO₂) measured with pulse oximetry. The black crosses for patients 2 and 3 indicate that we do not have the arterial saturation data in these two cases. The white (patterned) bars refer to StO₂ changes on the side ipsilateral (contralateral) to the ECT discharge, while the black bars refer to SaO₂ changes. The error bars are the standard deviations of the measurements.

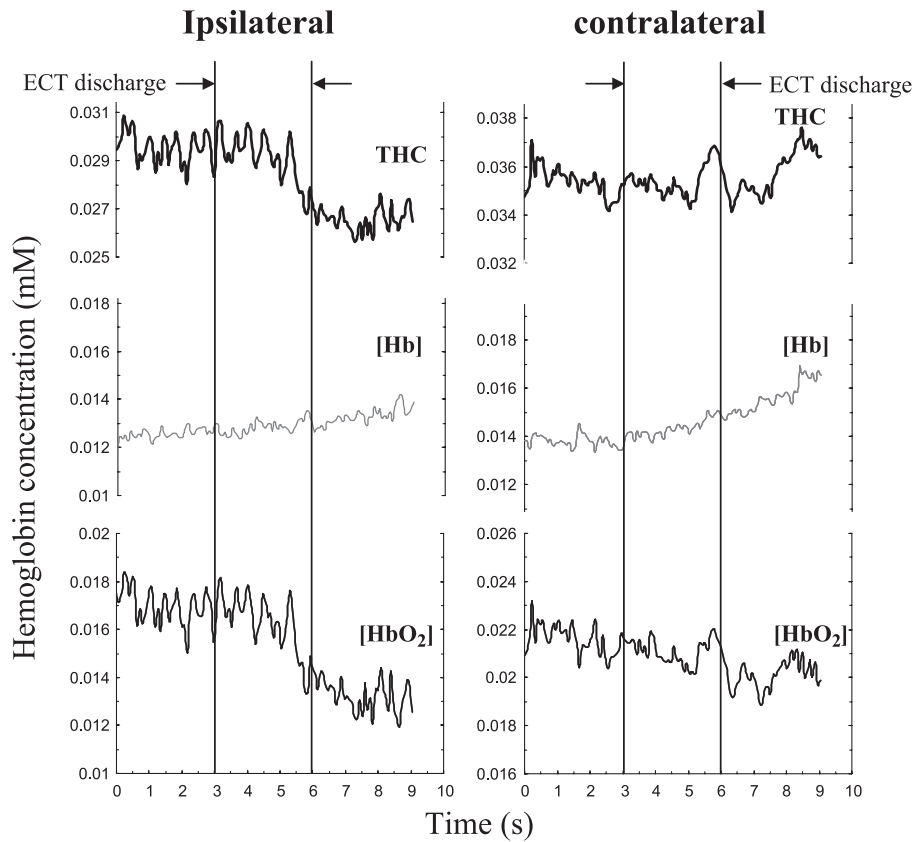


Fig. 6. Average across patients of the temporal traces of [Hb], [HbO₂], and THC during a 9-s temporal window consisting of 3 s pre-discharge, 3 s of discharge, and 3 s post-discharge.

(average \pm standard deviation over 10 s before the discharge) and the maximal changes in the 30 s following the discharge onset, as discussed in Section 2.2. In all patients, we have found that the ipsilateral decrease in the cerebral oxygenation significantly exceeds the contralateral decrease [we even observed a contralateral increase in the cerebral oxygenation in patients 2, 3, and 5 (3rd session)]. This result is summarized in Fig. 5, which reports the maximal changes in the arterial saturation, and in the ipsilateral and contralateral cerebral oxygenation (StO₂). A *t*-test analysis shows that the differences in the changes of StO₂ between ipsilateral and contralateral sides are significant ($P < 0.01$). Overall, the ipsilateral deoxygenation was $-21 \pm 5\%$, while the contralateral deoxygenation was $-6 \pm 4\%$ (average change \pm average standard deviation over the nine patients).

The arterial saturation decreases significantly during the seizure in four patients, namely patients 1, 4, 8, and 9. For these patients, the average decrease in the arterial saturation was $-19 \pm 4\%$. In patients 5 (in all three measured sessions), 6, and 7, we did not observe a significant seizure-induced change in the arterial saturation. During the measurements on two patients, namely patients 2 and 3, the pulse oximeter probe was inadvertently displaced by the ECT staff while monitoring the patient's conditions; as a

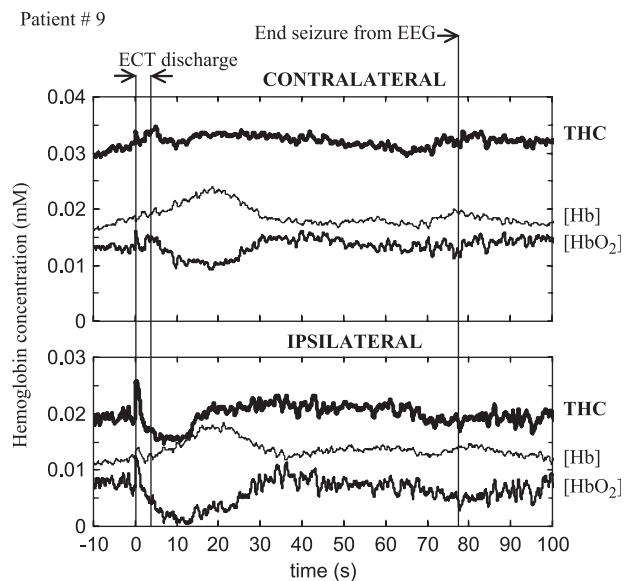


Fig. 7. Representative traces of the cerebral oxy-hemoglobin concentration ([HbO₂]), deoxy-hemoglobin concentration ([Hb]), and total hemoglobin concentration (THC=[HbO₂]+[Hb]) measured in one patient (9) during ECT. The top three traces refer to the brain side contralateral to the ECT discharge, while the bottom three traces refer to the ipsilateral side.

result, we have lost the arterial saturation data for these two patients.

3.2. Cerebral concentrations of oxy-hemoglobin ($[HbO_2]$), deoxy-hemoglobin ($[Hb]$), and total hemoglobin (THC)

The behavior of $[HbO_2]$, $[Hb]$, and THC during the application of the electrical current can be seen in detail in Fig. 6, which shows the average of the temporal traces recorded on all patients in a 9-s temporal window, including the last 3 s pre-discharge, the 3 s of discharge, and the first 3 s post-discharge. In Fig. 6 the hemodynamic changes during the electrical discharge show lateral

differences; on the ipsilateral side, we observed a larger decrease in the $[HbO_2]$ with respect to the contralateral side, while $[Hb]$ showed a smaller (not significant) increase in the ipsilateral side with respect to the contralateral side. As a result, the ipsilateral THC decreases during the discharge, while the contralateral changes in $[HbO_2]$ and $[Hb]$ compensate each other to yield a constant contralateral THC.

The typical behavior of the cerebral $[HbO_2]$, $[Hb]$, and THC during the ECT protocol is shown in Fig. 7, which refers to patient 9. After the end of the electrical discharge, $[HbO_2]$ decreases while $[Hb]$ increases on both sides, and they typically resume their respective baseline values before the

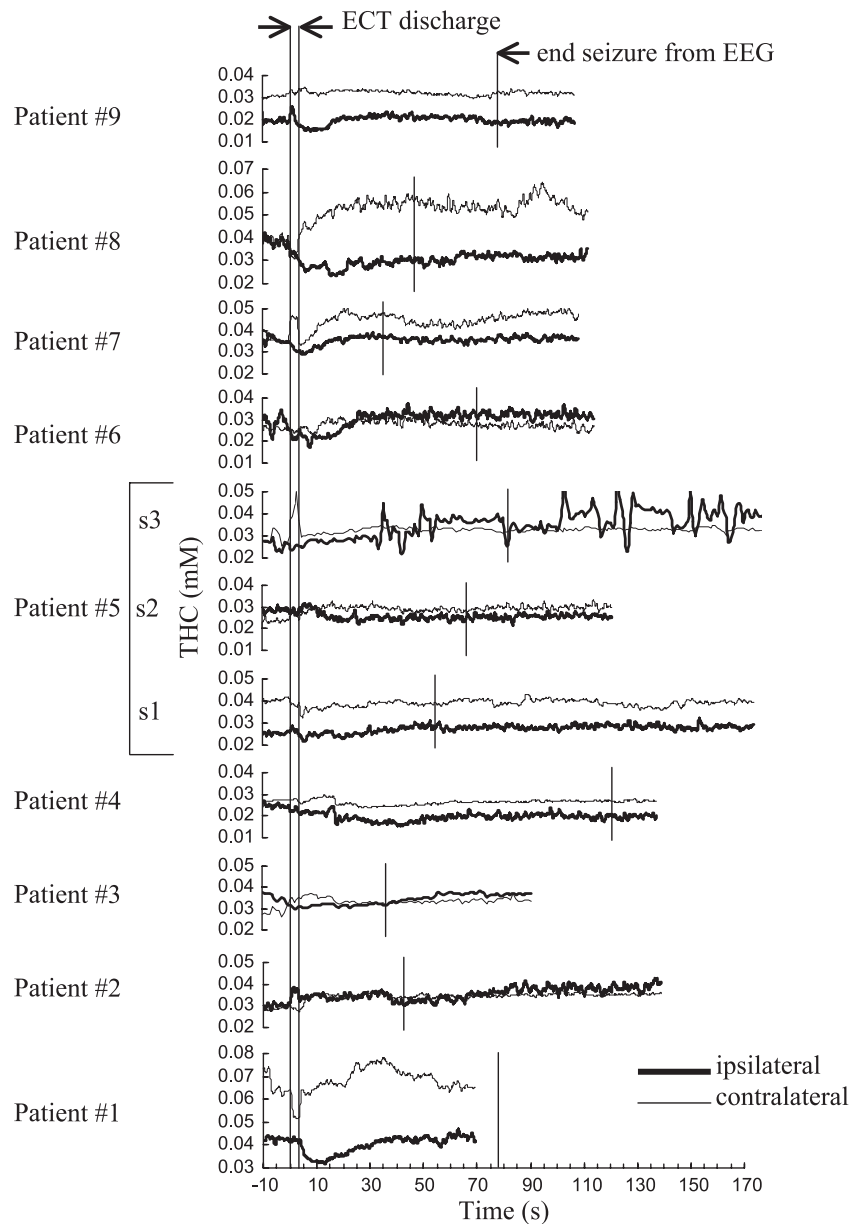


Fig. 8. Temporal traces of cerebral total hemoglobin concentration (THC) recorded with near-infrared spectroscopy on the sides ipsilateral (right) or contralateral (left) to the application of right unilateral ECT for all patients.

end of the seizure. While the post-ECT-discharge behavior of $[\text{HbO}_2]$ and $[\text{Hb}]$ is qualitatively similar on the ipsilateral and contralateral sides, the net effect represented by the total hemoglobin concentration ($\text{THC}=[\text{HbO}_2]+[\text{Hb}]$) shows lateral differences. Fig. 8 reports the temporal traces for THC for all patients and for both sides and Table 1 reports the baseline value and the maximal changes observed in the 30 s post-discharge for the total hemoglobin concentration. On the ipsilateral side, the THC consistently decreases after the ECT discharge (with the only exceptions of patient 2), while on the contralateral side, the THC typically increases. Overall, the post-discharge THC change was $-7 \pm 3 \mu\text{M}$ in the ipsilateral side and $6 \pm 3 \mu\text{M}$ in the contralateral side (average change \pm average standard deviation over the nine patients). A *t*-test analysis shows that the differences in the changes of THC between ipsilateral and contralateral are significant ($P < 0.01$).

3.3. Therapeutic response to ECT

The patients involved in this study have been classified as responders, partial-responders, or non-responders to ECT on the basis of the level of amelioration of their symptoms following the full treatment protocol (which involves 10–12 ECT sessions over 4–6 weeks). In responders, the main symptoms of major depression were resolved without short-term relapse; in partial responders, there was either a temporary disappearance of the symptoms, or the resolution of only some of the pre-ECT symptoms; non-responders have not shown a significant improvement to their depressive status after the ECT treatment. In our study, patients 2, 6, and 9 were responders, patients 1, 3, 4, 5, and 8 were partial-responders, and patient 7 was a non-responder.

Our NIRS measurements of the cerebral deoxygenation during the ECT-induced seizure (ΔStO_2) indicate a possible correlation between the ipsilateral brain deoxygenation and the therapeutic response to ECT. Fig. 9 shows that, on average, the ipsilateral decrease of StO_2 during seizure is the strongest for responders (three patients), intermediate for partial-responders (five patients), and the smallest for the

non-responder (one patient) (in Fig. 9 the error bars represent the average errors on the individual ΔStO_2 measurements). Of course, we must observe that the small number of patients reported here does not give statistical significance to the data reported in Fig. 9, which should be considered as a preliminary report of the potential of NIRS in the prediction of response to ECT.

4. Discussion

In Figs. 4 and 8, and in Table 1 one can observe the relatively large interpatient and lateral variability of the absolute baseline values of THC and StO_2 measured with NIRS. Such a variability is caused, (at least in part) by systematic errors in the optical measurements. In fact, absolute optical measurements of hemoglobin concentration in biological tissue require a quantitative model of light propagation inside the tissue. In our case, we have used a diffusion model for a semi-infinite homogeneous medium. However, the human head is neither semi-infinite nor homogeneous. The interpatient and lateral reliability in the head geometry accounts for model-related systematic errors in the absolute measurements. Because these systematic errors largely cancel out in the relative measurements of temporal changes in THC and StO_2 , we focus our discussion on the analysis of the hemodynamic and oxygenation changes associated with the electrical discharge and with the seizure.

Two major features of the NIRS measurements were common to all or most of the patients. Firstly, during the seizure induced by the right unilateral ECT, we consistently observed a decrease in the cerebral oxygenation. This finding is in agreement with the work of Saito et al. [24] who observed a cerebral deoxygenation by NIRS measurements at one location of the patient's forehead during bilateral ECT treatment. In addition, we have observed a different level of deoxygenation on the ipsilateral and contralateral sides; while we always observed a deoxygenation on the ipsilateral side, on the contralateral side we observed a deoxygenation in eight measurements and an increase of the cerebral oxygenation in three measurements (patients 2, 3, and 5 (3rd session)). In all cases, the contralateral decrease in cerebral deoxygenation was smaller than the ipsilateral decrease. These results indicate the relevance of bilateral measurements during right unilateral ECT and demonstrate the regional dependence of the cerebral oxygenation during ECT. As a result, the systemic oxygenation monitor provided by pulse oximetry may be insufficient to assess the adequacy of oxygen delivery to the brain during ECT. This latter point is further strengthened by the fact that in a number of cases (patients 5 in three sessions, 6, and 7) we recorded a significant cerebral deoxygenation with NIRS, but negligible arterial desaturation with pulse oximetry. Nevertheless, pulse oximeter is the only oxygenation monitoring tool available to the ECT

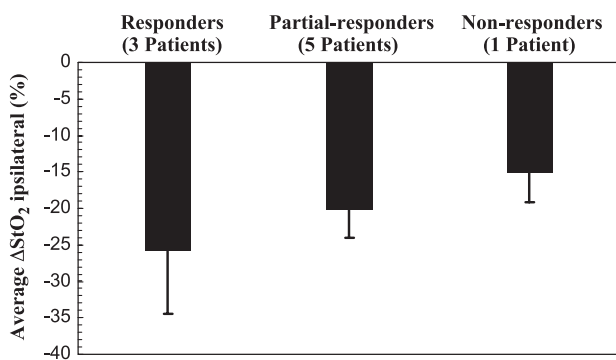


Fig. 9. Average ipsilateral change in the cerebral oxygenation for the three responders, five partial responders, and one non-responder to ECT treatment.

operators during treatment. We found that a significant decrease in SaO₂ during seizure accounts for a longer recovery time of the cerebral saturation (StO₂), as shown by the comparison between Fig. 3a and b.

The second consistent result is the decrease in the cerebral THC on the side ipsilateral to the ECT electrical discharge (with the single exception of patient 2). A key point to interpret this result is the behavior of [HbO₂] (decrease) and [Hb] (no change) on the ipsilateral side during the 3 s of ECT discharge (see Fig. 6). A decrease in [HbO₂] and a concurrent lack of change of ipsilateral [Hb] are consistent with a vascular contraction (caused by the electrical current through the brain) and a simultaneous increase in the cerebral metabolic rate of oxygen (caused by the electrically induced seizure). In fact, the vascular contraction causes a decrease in both [HbO₂] and [Hb], while an increase in oxygen consumption causes a further decrease in [HbO₂] and an increase in [Hb] that can compensate the decrease induced by vascular contraction [6]. This observation suggests that the current-induced vascular contraction introduces a significant difference between electrically induced seizures and spontaneous or chemically induced seizures. In fact, THC has been observed to increase during spontaneous [1,26,29,32] or chemically induced [34], whereas we have found an ipsilateral decrease in THC during unilateral ECT and Saito et al. [23] found an initial THC decrease in response to bilateral ECT. Saito et al. assigned the observed initial decrease in THC during bilateral ECT to a current-induced contraction of the arterial wall smooth muscle, which is in agreement with our analysis. The fact that this vascular constriction effect is directly associated with the electrical current is further confirmed in our unilateral ECT study by the fact that the contralateral THC decreased in only three of the nine patients examined.

Our two major results, namely the consistent ipsilateral decrease in THC and cerebral oxygenation, indicate a reduction of the regional blood flow (rCBF) in the right frontal cortex during seizures induced by right unilateral ECT. Furthermore, the observed contralateral increase in THC and the smaller contralateral (with respect to ipsilateral) cerebral deoxygenation (see Table 1), shows that the rCBF responds differently in the right and left frontal regions. Acute effects of right unilateral ECT on the rCBF have been studied using the 133-xenon inhalation technique and multiple scintillation detectors for spatially resolved measurements [20,21,27]. These studies were performed pre-ictally (immediately before [27], 25 min before [21], or 30 min before [20]) and post-ictally (2 h after [27], or 50 min after [20,21]). All these studies found that the rCBF decreases most significantly in the right frontal areas following right unilateral ECT. Furthermore, it was suggested that the magnitude of the decrease of rCBF correlates with the clinical outcome of ECT [20]. However, these 133-xenon inhalation studies, as well as other studies that also found reductions in CBF following ECT using the nitrous oxide method [16], single-

photon emission computed tomography [25], and positron emission tomography [33], are not applicable during (and not even immediately after) the ECT treatment. Near-infrared spectroscopy is unique in this respect, as it can be performed during the application of the electrical current and the resulting seizure. As a result, NIRS can shed light on the origin of the lateral difference in post-ictal rCBF (whereas symmetrical post-ictal reductions in rCBF were observed following bilateral ECT [20,21,27]). Fig. 6 and its interpretation given above suggest that a vascular constriction directly associated with the delivery of the electrical current to the right brain hemisphere may be at the origin of the lateral differences in the rCBF response to unilateral ECT. The flow reductions observed 50 minutes post-seizure may be mediated by local biochemical effects associated with the seizure, as proposed by Prohvnik et al. [21].

The fact that post-seizure changes in blood flow have been observed to correlate with the therapeutic outcome of ECT [20] suggest that NIRS, which is exquisitely sensitive to the cerebral hemodynamics and oxygenation, may be able to identify physiological patterns (during or immediately after seizure) that correlate with clinical outcome. This is of particular importance because a full ECT treatment consists of a series of 10–12 sessions over a period of 4–6 weeks. Therefore, it would be important to be able to identify non-responders during early sessions, so that they would not have to undergo the full series of ECT sessions. We have argued that the origin of the difference in the pattern of cerebral blood volume changes observed during electrically induced seizure (decrease) with respect to spontaneous seizures (increase) is the vascular constriction induced by the electrical current. This process involves the side of the brain that is ipsilateral to the side of current application in unilateral ECT. For this reason, we have chosen to display the ipsilateral cerebral deoxygenation during seizure in Fig. 9. However, a number of different hemodynamic/oxygenation parameters can be derived from NIRS data, and it is possible that some of these parameters correlate more strongly with therapeutic response to ECT. In this study, the paucity of the clinical data does not allow us to draw statistically significant conclusions on the effectiveness of NIRS in predicting clinical outcome of ECT. Therefore, we have not investigated and compared the performance of different combinations of NIRS data in predicting therapeutic response. This would require a more extended clinical study. The purpose of Fig. 9 is to illustrate the clinical potential of NIRS in ECT, which is based on the observed correlation between cerebral blood flow changes and therapeutic response [20], and on the effectiveness of NIRS in monitoring cerebral blood volume and oxygenation changes during ECT, as demonstrated in this article.

One potentially confounding factor in all non-invasive, near-infrared studies of the brain is the sensitivity of the technique to extracerebral tissue (scalp, skull, cerebrospinal fluid, dura, etc.) in addition to brain tissue. As a result, it may be difficult to separate the contributions to the optical

measurements that originate in the brain from those that originate in more superficial tissue layers. In this particular study, the effects of the current delivery on local muscle metabolism may induce optical changes on superficial muscle layers. While sensitivity to superficial tissue layers is a common limitation of the non-invasive NIRS of the human brain, our unique multi-distance approach to NIRS minimizes such a sensitivity to superficial tissue layers. In fact, by performing measurements on tissue-like phantoms, it has been shown that multi-distance NIRS measurements are relatively insensitive to the superficial tissue layers (down to a depth of ~ 4 mm) [8], which include scalp, lipid layer, and muscle in the frontal region. Furthermore, the lateral differences in the response to the unilateral ECT found by us are consistent with lateral differences in rCBF reported in literature as discussed above, and further support the fact that our NIRS results are indeed representative of cerebral metabolic and blood flow changes.

5. Conclusions

We have presented bilateral NIRS measurements of the cerebral concentration and oxygen saturation of hemoglobin on the frontal region of nine patients undergoing electroconvulsive therapy. The bilateral measurement approach is important to study the hemodynamic effects of electrically induced seizures during unilateral ECT treatment. In fact, we have found asymmetric changes in the cerebral blood volume and oxygenation measured on the frontal areas ipsilateral and contralateral to the side of the electrical discharge. More specifically, during the seizure we have observed a generalized cerebral deoxygenation, even in the absence of peripheral arterial desaturation, which was consistently more pronounced on the side of the electrical discharge (ipsilateral side); overall, the ipsilateral deoxygenation was $-21 \pm 5\%$ as opposed to a contralateral deoxygenation of $-6 \pm 4\%$ (average values \pm average standard deviation across the nine patients). Furthermore, during the seizure we have consistently observed a decrease in the cerebral hemoglobin concentration on the ipsilateral side ($-7 \pm 3 \mu\text{M}$), while on the contralateral side we have observed an increase ($6 \pm 3 \mu\text{M}$). The asymmetric changes observed during the seizure are assigned to a vascular constriction that is directly associated with the electrical discharge through the right side of the brain in right unilateral ECT. The asymmetric hemodynamic/oxygenation changes observed in this study in response to unilateral ECT are consistent with the asymmetric reductions in the frontal rCBF following right unilateral ECT reported in literature using different methods [20,21,27].

It has been shown that the magnitude of the rCBF reduction correlates with the clinical outcome of ECT [20]. In this pilot study, the small number of patients does not allow us to demonstrate the effectiveness of NIRS in predicting the clinical outcome of ECT. However, the

preliminary clinical findings reported here are prompting new studies to investigate the potential of NIRS in the ECT clinical practice.

Acknowledgements

We thank the ECT nursing staff at McLean Hospital for their technical assistance. This research is supported in part by the National Science Foundation Award No. BES-93840, and by the National Institutes of Health Grants Nos. DA14178, MH62854, and MH64175.

References

- [1] P.D. Adelson, E. Nemoto, M. Scheuer, M. Painter, J. Morgan, H. Yonas, Noninvasive continuous monitoring of cerebral oxygenation periodically using near-infrared spectroscopy: a preliminary report, *Epilepsia* 40 (1999) 1484–1489.
- [2] C.E. Coffey, J. Lucke, R.D. Weiner, A.D. Krystal, M. Aque, Seizure threshold in electroconvulsive therapy (ECT): II. The anticonvulsant effect of ECT, *Biological Psychiatry* 37 (1995) 777–788.
- [3] C.E. Coffey, J. Lucke, R.D. Weiner, A.D. Krystal, M. Aque, Seizure threshold in electroconvulsive therapy (ECT): I. Initial seizure threshold, *Biological Psychiatry* 37 (1995) 713–720.
- [4] G.D. d'Elia, Unilateral electroconvulsive therapy, in: M. Fink, S. McGaugh, J. McGaugh (Eds.), *Psychobiology of Convulsive Therapy*, Winston & Sons, Washington, DC, 1974.
- [5] G. d'Elia, C. Perris, Comparison of electroconvulsive therapy with unilateral and bilateral stimulation: I. Seizure and post-seizure electroencephalographic pattern, *Acta Psychiatrica Scandinavica Supplementum* 215 (1970) 9–29.
- [6] S. Fantini, A haemodynamic model for the physiological interpretation of in vivo measurements of the concentration and oxygen saturation of haemoglobin, *Physics in Medicine and Biology* 47 (2002) 249–257.
- [7] S. Fantini, M.A. Franceschini, J.B. Fishkin, B. Barbieri, E. Gratton, Quantitative determination of the absorption spectra of chromophores in strongly scattering media: a light-emitting-diode based technique, *Applied Optics* 33 (1994) 5204–5213.
- [8] M.A. Franceschini, S. Fantini, L.A. Paunescu, J.S. Maier, E. Gratton, Influence of a superficial layer in the quantitative spectroscopic study of strongly scattering media, *Applied Optics* 37 (1998) 7447–7458.
- [9] S.P. Gopinath, C.S. Robertson, R.G. Grossman, B. Chance, Near-infrared spectroscopic localization of intracranial hematomas, *Journal of Neurosurgery* 79 (1993) 43–47.
- [10] G. Gratton, J.S. Maier, M. Fabiani, W.W. Mantulin, E. Gratton, Feasibility of intracranial near-infrared optical scanning, *Psychophysiology* 31 (1994) 211–215.
- [11] G. Gratton, M. Fabiani, D. Friedman, M.A. Franceschini, S. Fantini, P.M. Corballis, E. Gratton, Rapid changes of optical parameters in the human brain during a tapping task, *Journal of Cognitive Neuroscience* 7 (1995) 446–456.
- [12] M.E. Henry, M.E. Schmidt, J.A. Matochik, P.E. Stoddard, P. Eve, W.Z. Potter, The effects of ECT on brain glucose: a pilot FDG PET study, *Journal of ECT* 17 (2001) 33–40.
- [13] Y. Hoshi, M. Tamura, Dynamic changes in cerebral oxygenation in chemically induced seizures in rats: study by near-infrared spectrophotometry, *Brain Research* 603 (1993) 215–221.
- [14] F.F. Jöbsis, Noninvasive, infrared monitoring of cerebral and myocardial oxygen sufficiency and circulatory parameters, *Science* 198 (1977) 1264–1267.
- [15] T. Kato, A. Kamei, S. Takashima, T. Ozaki, Human visual cortical function during photic stimulation monitoring by means of near-infra-

- red spectroscopy, *Journal of Cerebral Blood Flow and Metabolism* 13 (1993) 516–520.
- [16] S.S. Kety, R.B. Woodford, M.H. Harmel, F.A. Freyhan, K.E. Appel, C.F. Schmidt, Cerebral blood flow and metabolism in schizophrenia, *American Journal of Psychiatry* 104 (1948) 765–770.
- [17] A. Maki, Y. Yamashita, Y. Ito, E. Watanabe, Y. Mayanagi, H. Koizumi, Spatial and temporal analysis of human motor activity using non-invasive NIR topography, *Medical Physics* 22 (1995) 1997–2005.
- [18] P.W. McCormick, M. Stewart, G. Lewis, M. Dujovny, J.I. Ausman, Intracerebral penetration of infrared light: technical note, *Journal of Neurosurgery* 76 (1992) 315–317.
- [19] J.H. Meek, C.E. Elwell, M.J. Khan, J. Romaya, J.S. Wyatt, D.T. Delpy, S. Zeki, Regional changes in cerebral haemodynamics as a result of a visual stimulus measured by near infrared spectroscopy, *Proceedings of the Royal Society of London, B*, vol. 261, 1995, pp. 351–356.
- [20] M.S. Nobler, H.A. Sackeim, I. Prohovnik, J.R. Moeller, S. Mukherjee, D.B. Schnur, J. Prudic, D.P. Devanand, Regional cerebral blood flow in mood disorders: III. Treatment and clinical response, *Archives of General Psychiatry* 51 (1994) 884–897.
- [21] I. Prohovnik, H.A. Sackeim, P. Decina, S. Malitz, Acute reductions of regional cerebral blood flow following electroconvulsive therapy, Interactions with Modality and Time, *Annals of the New York Academy of Sciences* 462 (1986) 249–262.
- [22] H.A. Sackeim, J. Prudic, D.P. Devanand, M.S. Nobler, S.H. Lisanby, S. Peyser, L. Fitzsimons, B.J. Moody, J. Clark, A prospective, randomized, double-blind comparison of bilateral and right unilateral electroconvulsive therapy at different stimulus intensities, *Archives of General Psychiatry* 57 (2000) 425–434.
- [23] S. Saito, D. Yoshikawa, Y. Nishihara, T. Morita, Y. Kitani, T. Amaya, T. Fujita, The cerebral hemodynamic response to electrically induced seizures in man, *Brain Research* 673 (1995) 93–100.
- [24] S. Saito, S. Miyoshi, D. Yoshikawa, H. Shimada, T. Morita, Y. Kitani, Regional cerebral oxygen saturation during electroconvulsive therapy: monitoring by near-infrared spectrophotometry, *Anesthesia and Analgesia* 83 (1996) 726–730.
- [25] A.I.F. Scott, N. Dougall, M. Ross, R.E. O'Carroll, W. Riddle, K.P. Ebmeier, G.M. Goodwin, Short-term effects of electroconvulsive treatment on the uptake of technetium-99m-exametazime into brain in major depression shown with single photon emission tomography, *Journal of Affective Disorder* 30 (1994) 27–34.
- [26] M. Shichiri, T. Tanabe, K. Hara, S. Suzuki, E. Wakamiya, H. Tamai, Usefulness of near-infrared spectroscopy for identification of epileptic foci in two localization-related epilepsy patients, *No To Hattatsu* 33 (2001) 475–479.
- [27] P. Silfverskiold, L. Gustafson, J. Risberg, I. Rosen, Acute and late effects of electroconvulsive therapy: clinical outcome, regional cerebral blood flow, and electroencephalogram, *New York Academy of Sciences* 462 (1986) 236–248.
- [28] D.K. Sokol, O.N. Markand, E.C. Daly, T.G. Luerssen, M.D. Malkoff, Near infrared spectroscopy (NIRS) distinguishes seizure types, *Seizure* 9 (2000) 323–327.
- [29] B.J. Steinhoff, G. Herrendorf, C. Kurth, Ictal near infrared spectroscopy in temporal lobe epilepsy: a pilot study, *Seizure* 5 (1996) 97–101.
- [30] A. Tasman, J. Kay, J.A. Lieberman, *Psychiatry*, Chapter 80, in: *Electroconvulsive Therapy*, vol. 2, Saunders, Philadelphia, 1997.
- [31] A. Villringer, J. Planck, C. Hock, L. Schleinkofer, U. Dirnagl, Near infrared spectroscopy (NIRS): a new tool to study hemodynamic changes during activation of brain function in human adults, *Neuroscience Letters* 154 (1993) 101–104.
- [32] A. Villringer, J. Planck, S. Stodieck, K. Botzel, L. Schleinkofer, U. Dirnagl, Noninvasive assessment of cerebral hemodynamics and tissue oxygenation during activation of brain cell function in human adults using near infrared spectroscopy, *Advances in Experimental Medicine and Biology* 345 (1994) 559–565.
- [33] N.D. Volkow, S. Bellar, N. Mullani, L. Jould, S. Dewey, Effects of electroconvulsive therapy on brain glucose metabolism: a preliminary study, *Convulsive Therapy* 4 (1988) 199–205.
- [34] E. Watanabe, A. Maki, F. Kawaguchi, Y. Yamashita, H. Koizumi, Y. Mayanagi, Noninvasive cerebral blood volume measurement during seizures using multichannel near infrared spectroscopic topography, *Journal of Biomedical Optics* 5 (2000) 287–290.
- [35] M. Yanagida, M. Tamura, Changes in oxygenation states of rat brain tissue during glutamate-related epileptical seizures-near-infrared study, in: P. Vaupel (Ed.), *Oxygen Transport to Tissue*, vol. XV, Plenum Press, New York, 1994, pp. 417–422.